

Osteomyelitis and Endocarditis Due to Brucellosis

Farzin Khorvash¹; Shiva Shabani^{2,*}

¹Nosocomial Infection Research Center, Isfahan University of Medical Sciences, Isfahan, IR Iran

²Isfahan University of Medical Sciences, Isfahan, IR Iran

*Corresponding author: Shiva Shabani, Nosocomial Infection Research Center, Isfahan University of Medical Sciences, Isfahan, IR Iran. Tel: +98-3113359359, Fax: +98-3113373735, E-mail: dr.shiva_shabani90@yahoo.com

Received: January 15, 2015; Revised: March 4, 2015; Accepted: March 20, 2015

Introduction: Brucellosis is a multi-systemic infectious disease characterized by fever, sweating, generalized malaise, weight loss, and arthralgia. Brucella Endocarditis (BE) is a serious complication of Brucellosis and occurs in 1% of all types of Brucella infections. Also, Brucella is one of the main causes of vertebral osteomyelitis. To the authors' best knowledge, to date there has been no report regarding the concurrence of endocarditis and osteomyelitis in Brucellosis.

Case Presentation: The current case was a 70-year-old female presented with fever and low back pain. The spinal Magnetic Resonance Imaging (MRI) was performed and signal changing in T9, T10 with probability of metastasis was reported. Before neurosurgical management, 2ME and Wright were checked and the titers were positive. Changing heart murmur, transthoracic, and transesophageal, and aortic-valve vegetation were detected in physical examinations and echocardiography. The patient was treated for six months and the low back pain improved and no vegetation was detected in echocardiography at the end of this period.

Conclusions: Physicians should consider Brucellosis in all patients with low back pain in the Brucella endemic regions, and in those with spondylitis or culture-negative IE in the Brucella endemic regions.

Keywords: Endocarditis; Osteomyelitis; Brucellosis

1. Introduction

Brucellosis is a multi-systemic infectious disease characterized by fever, chills, sweating, generalized malaise, weight loss, and arthralgia. It is usually observed in the developing countries of the Mediterranean and Middle-East regions (1). Brucella Endocarditis (BE) is a serious complication of Brucellosis and occurs in 1% of all types of Brucella infections; Brucella endocarditis usually affects the left side of the heart (2). Brucellosis is one of the main causes of vertebral osteomyelitis in the developing countries especially where Brucellosis is endemic, it should be considered in differential diagnosis of every spinal lesion. Computed Tomography (CT) and Magnetic Resonance Imaging (MRI) are up to 95% sensitive, but MRI affords better definition of paravertebral tissues and the spinal channel; therefore, MRI is suggested if vertebral osteomyelitis is suspected (3). The diagnosis of Brucellosis may be delayed or even entirely missed because of various and nonspecific clinical manifestations; therefore, a high level of suspicions is recommended (4). There are scanty data regarding the optimal treatment of endocarditis, but combinations of antibiotic regimen including aminoglycosides, such as doxycycline for three months and streptomycin for two to three weeks seem rational selections. Patients with spondylitis appear to respond to doxycycline for three months, plus streptomycin for two to three weeks (5). Surgery contributes to survival in

the selected endocarditis patients, such as the ones with congestive heart failure, valvular regurgitation, antibiotic resistant infections, embolic complications, or large vegetation (6).

2. Case Presentation

A 70-year-old female from Masjed-soleyman, Iran, was admitted with mild to moderate fever and low back pain. The problem began three months ago as a pain of left lower extremity radiating to the knee diagnosed as osteoarthritis, and the analgesic drugs was prescribed but no improvement was showed despite multiple reference to physician. Her pain continued and loss of appetite, anorexia, and weight loss were added. The patient was alert, oriented, had no difficulties in breathing and movement, also no tenderness in abdominal palpation, percussion, or organomegaly was assessed. A grade 6 systolic murmur was heard at the center of aorta. Then she was referred to neurosurgeon who recommended spinal MRI. The spinal MRI was performed and signals changing in T9, T10 with probability of metastasis was reported (Figure 1). In microscopic study of T9 biopsy, there was thinning of trabecular bone with 70% cellularity of bone marrow and increases of lymphocytes; and Immunohistochemical (IHC) was recommended.

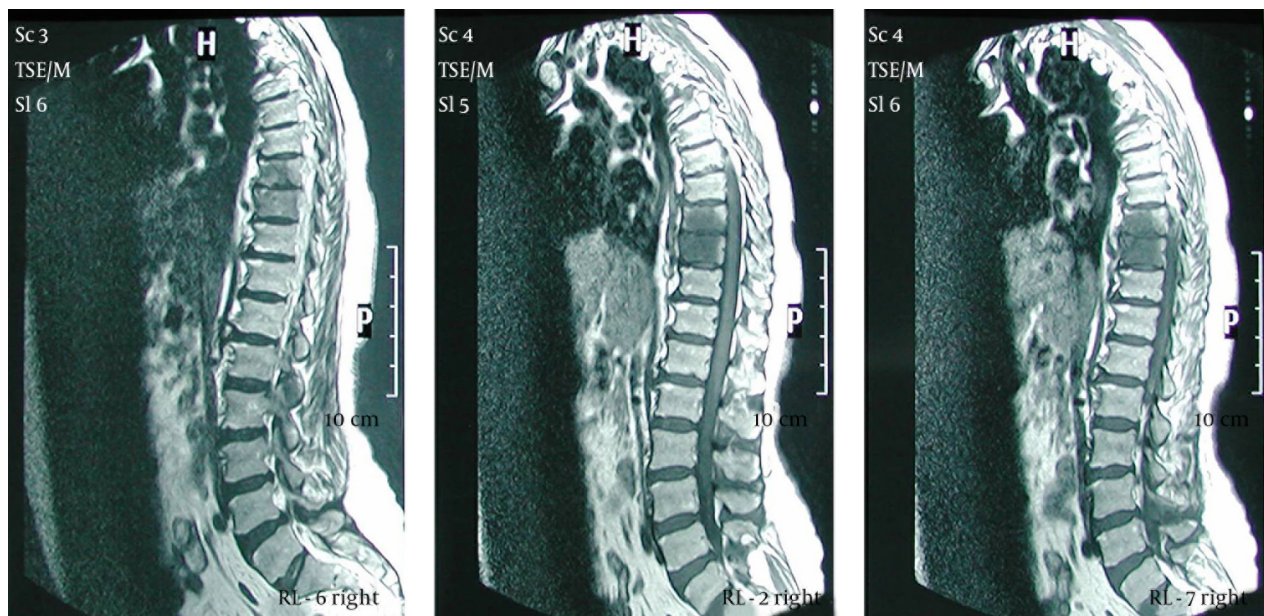
In the IHC study, bone marrow hypercellularity without metastatic changes was reported. Before neurosurgical management, infectious diseases consultation was performed and according to this consultation Wright and 2ME were checked. Result was as follow: Wright = 1/160; 2ME = 1/160; ESR = 50 (mm/hr); CRP = 330; WBC = 6300 (per mm³); Neutrophil = 60%; Lymph = 40%; Hb = 11.1 g/dL; BACTEC (Battle Area Clearance, Training, Equipment and Consultancy) for Brucella was negative. She was hospitalized for high heart murmur in the physical examinations; therefore, trans-esophageal echocardiography was performed that TTE vegetation on aortic-valve was reported. She occasionally had consumed contaminated meat but not raw milk. Finally she was treated by doxycycline and rifampin for six months, streptomycin for two weeks followed by cotrimoxazol for six months. After the operation of combination antibiotic treatment all morbidity signs such as fever and low back pain disappeared and she greatly improved at the end of the period.

3. Discussion

It is difficult to diagnose Brucella endocarditis. A changing heart murmur, high serologic titer for Brucella, and echocardiography are helpful (7). Brucellosis is one of the main causes of vertebral osteomyelitis in the developing countries. Brucella osteomyelitis may appear as a tumor lesion on radiographs. Thus, care should be taken during diagnosis of etiology of the lesions (8). The case in the current study was a 70-year-old female who presented clinical and serological markers

for three months. She was finally treated for Brucella endocarditis and osteomyelitis only with medical therapy. Previous similar studies on patients with BE showed that in the absence of a controlled trial, surgery should be part of the treatment and only medical therapy does not seem to be adequate in most cases (9). The current study patient had no cardiac failure and was treated with medical treatment. Although Brucella osteomyelitis needs longer treatment than non-focal forms, in this case endocarditis treatment covered osteomyelitis (10). Valve replacement may not be feasible for every patient in the developing countries. The exact role of medical treatment alone is not known in the management. Well documented cure of the patients by medical treatments are available in the English papers. Surgery contributes to survival in selected endocarditis patients such as the ones with congestive heart failure, valvular regurgitation, antibiotic resistant infections, embolic complications, or large vegetation (6). Up to now, several cases of Brucella osteomyelitis and, to a smaller extent, some cases of Brucella endocarditis are reported; however, the concurrency of osteomyelitis and endocarditis are interesting and rare. In the diagnostic process of patients with spondylitis or culture-negative IE in endemic regions for Brucella, Brucella in differential diagnosis should be considered. In the patients with Brucella endocarditis without signs and symptoms of heart failure, medication therapy alone can be successful. In select endocarditis patients, such as the ones with congestive heart failure, valvular regurgitation, antibiotic resistant infections, embolic complications, or large vegetation, surgery contributes to the patients' survival.

Figure 1. TEE Report LV EF: 55%



Artrioventricular electrogram.

Authors' Contributions

Farzin Khorvash: Original idea, diagnosis of disease and reading the manuscript; Shiva Shabani: data analysis, manuscript writing and preparing.

References

1. Ruiz J, Lorente I, Perez J, Simarro E, Martinez-Campos L. Diagnosis of brucellosis by using blood cultures. *J Clin Microbiol.* 1997;**35**(9):2417-8.
2. Ferreira P, Gama P, Correia J, Nunes L, Pipa J, Nascimento C, et al. Brucella endocarditis-case report and literature review. *Rev Port Cardiol.* 2008;**27**(10):1309-15.
3. Mohan V, Gupta RP, Marklund T, Sabri T. Spinal brucellosis. *Int Orthop.* 1990;**14**(1):63-6.
4. Barham WB, Church P, Brown JE, Paparello S. Misidentification of Brucella species with use of rapid bacterial identification systems. *Clin Infect Dis.* 1993;**17**(6):1068-9.
5. Koruk ST, Erdem H, Koruk I, Erbay A, Tezer-Tekce Y, Erbay AR, et al. Management of Brucella endocarditis: results of the Gulhane study. *Int J Antimicrob Agents.* 2012;**40**(2):145-50.
6. Russo T MG., Douglas R., Bennett J., Dolin R. *Principles and Practice of Pediatric Infectious Diseases.* New York: Churchill Livingstone; 2005.
7. Cohen PS, Maguire JH, Weinstein L. Infective endocarditis caused by gram-negative bacteria: a review of the literature, 1945-1977. *Prog Cardiovasc Dis.* 1980;**22**(4):205-42.
8. Fowler TP, Keener J, Buckwalter JA. Brucella osteomyelitis of the proximal tibia: a case report. *Iowa Orthop J.* 2004;**24**:30-2.
9. Esmailpour N, Borna S, Nejad MR, Badie SM, Badie BM, Hadadi A. Brucella endocarditis: a report from Iran. *Trop Doct.* 2010;**40**(1):47-9.
10. Al Dahouk S, Neubauer H, Hensel A, Schoneberg I, Nockler K, Alpers K, et al. Changing epidemiology of human brucellosis, Germany, 1962-2005. *Emerg Infect Dis.* 2007;**13**(12):1895-900.